

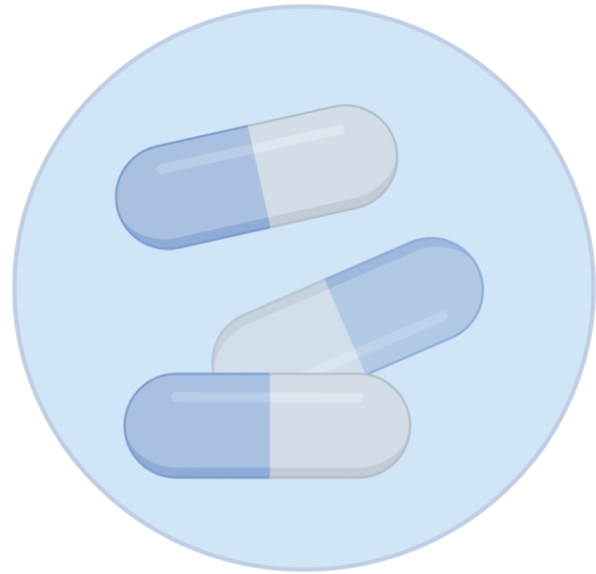# To Image or Not to Image

Chet Villa

Professor of Pediatrics

Cincinnati Children's Hospital Medical Center

# The Promise of Personalized Medicine



Right  
Therapy

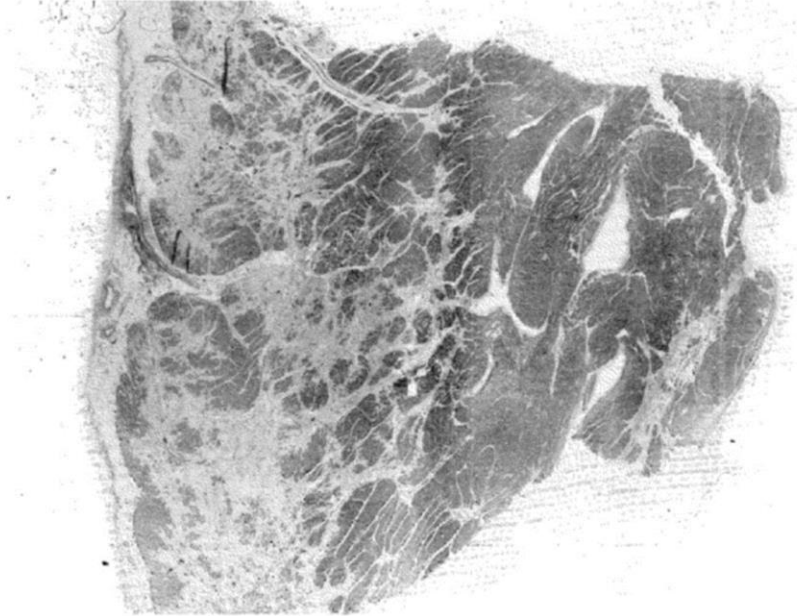


Right  
Time



Right  
Person

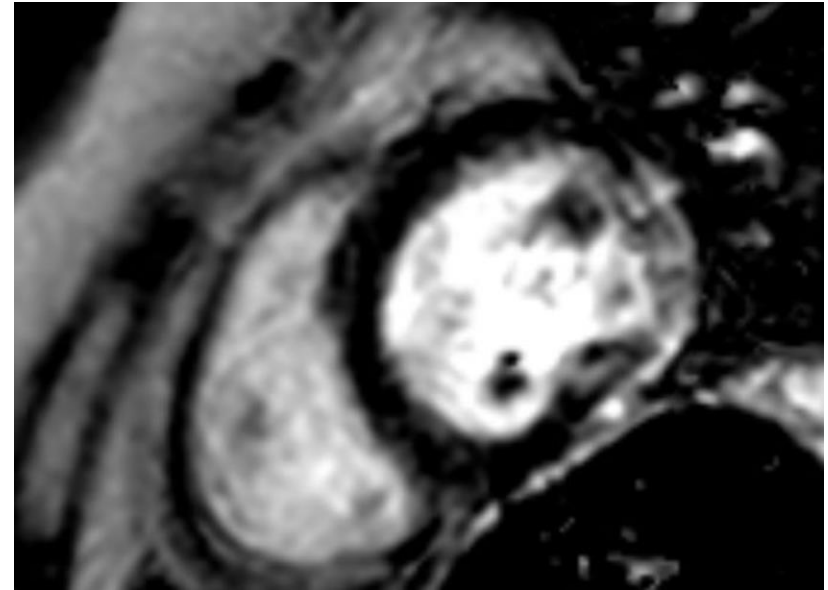
**Microscope  
1970s**



**Fibrosis**

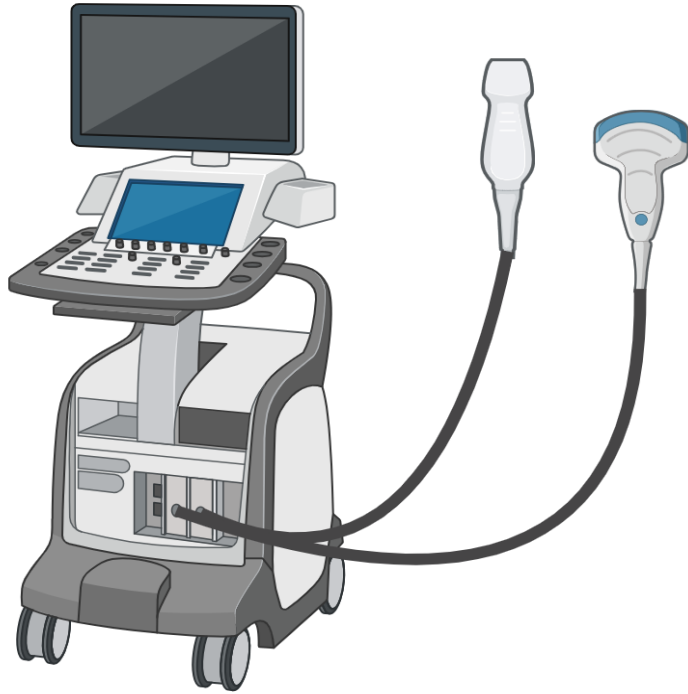


**Cardiac MRI  
2010s**

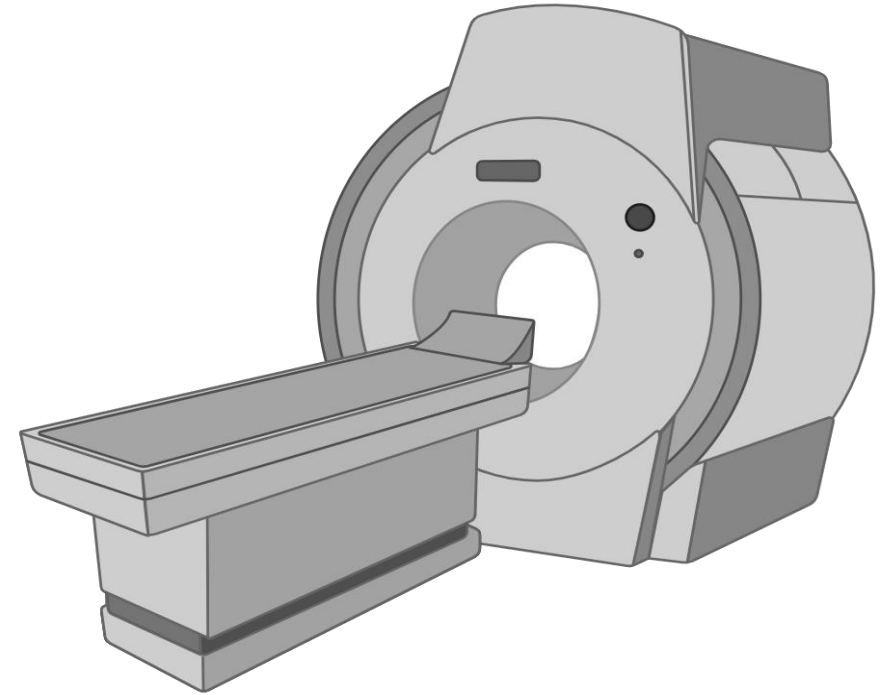


**Fibrosis**

# Assessing Heart Function



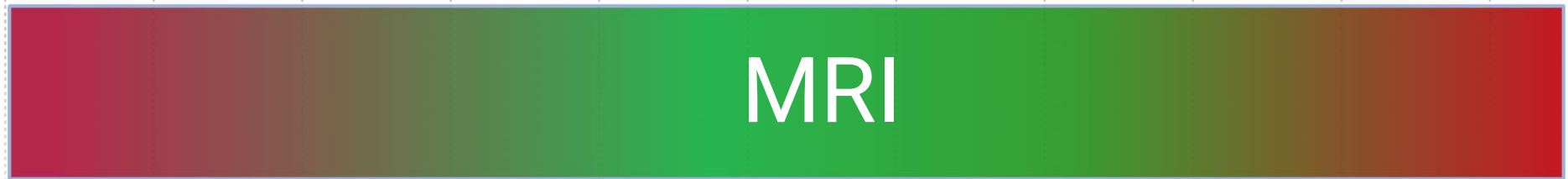Echocardiogram



Cardiac MRI

# AGE

0 3 6 8 12 15 18 21 24 27 30

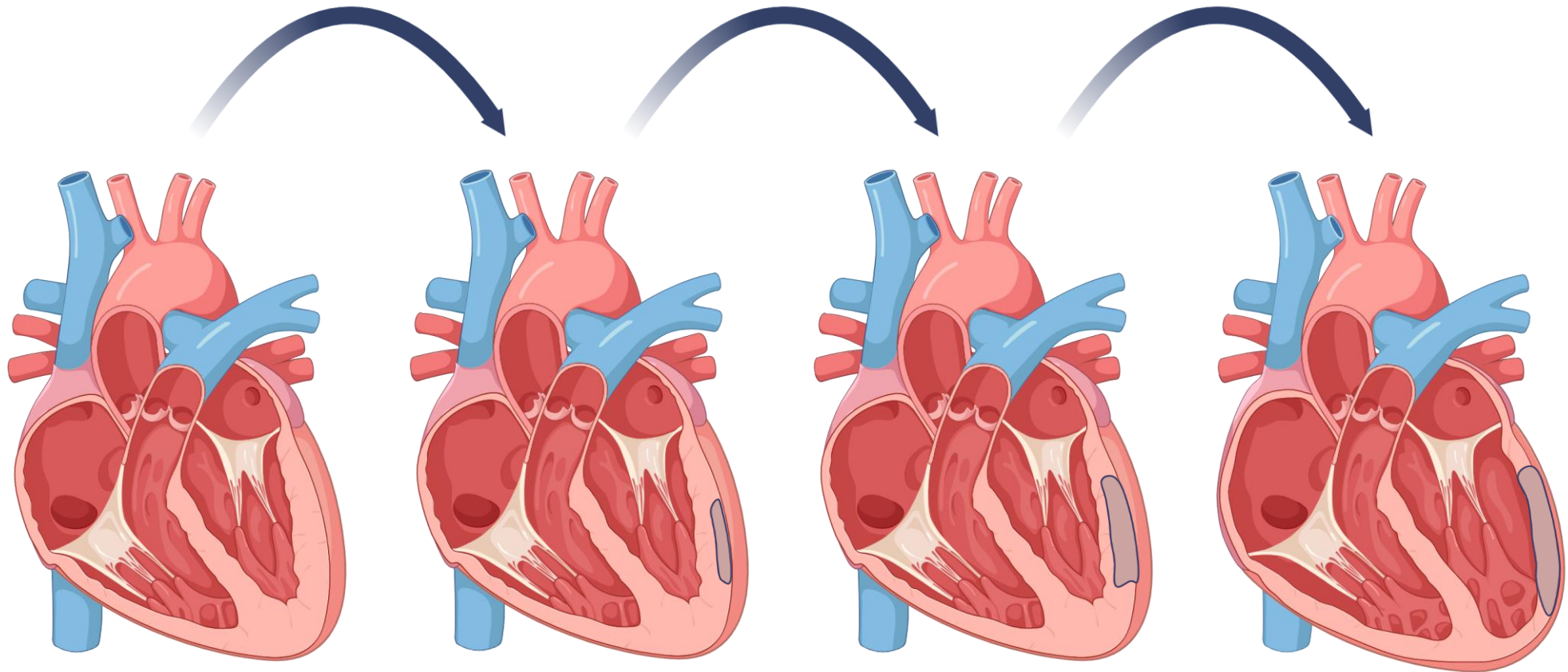


# How >2,500 MRIs Happen



# EVOLUTION IN OUR UNDERSTANDING OF DMD CARDIOMYOPATHY

---



Normal function  
No fibrosis

Normal function  
+ fibrosis

↓ function  
++ fibrosis

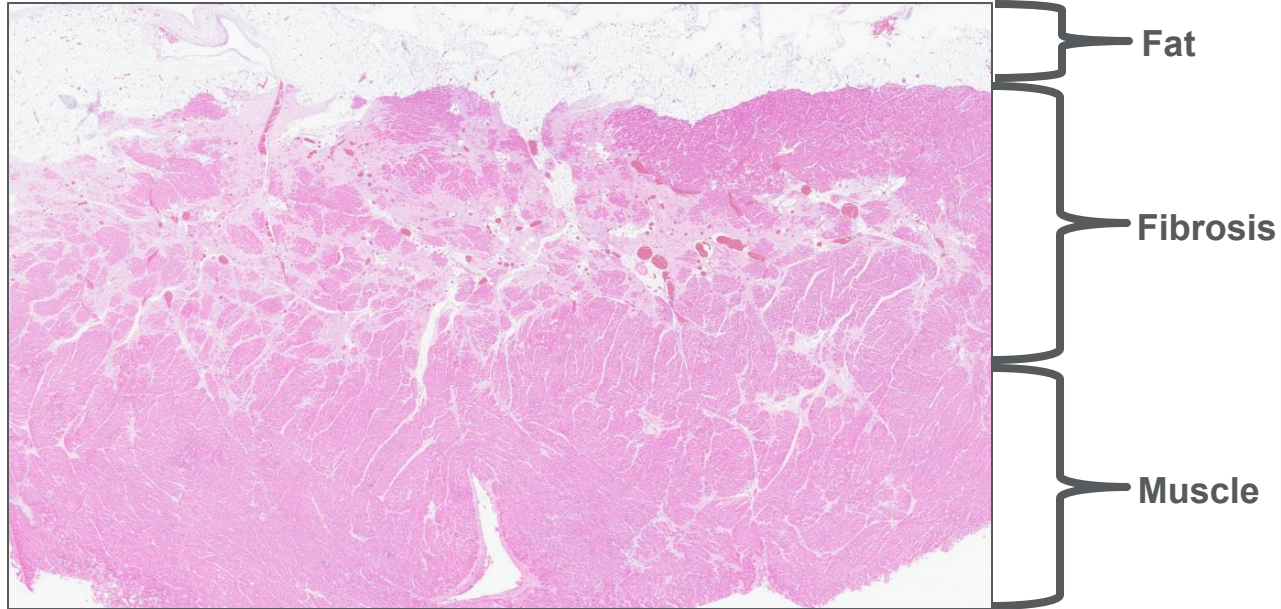
↓↓ function  
+++ fibrosis  
+ enlargement

# Recommendation: Start anti-fibrotics at age 10

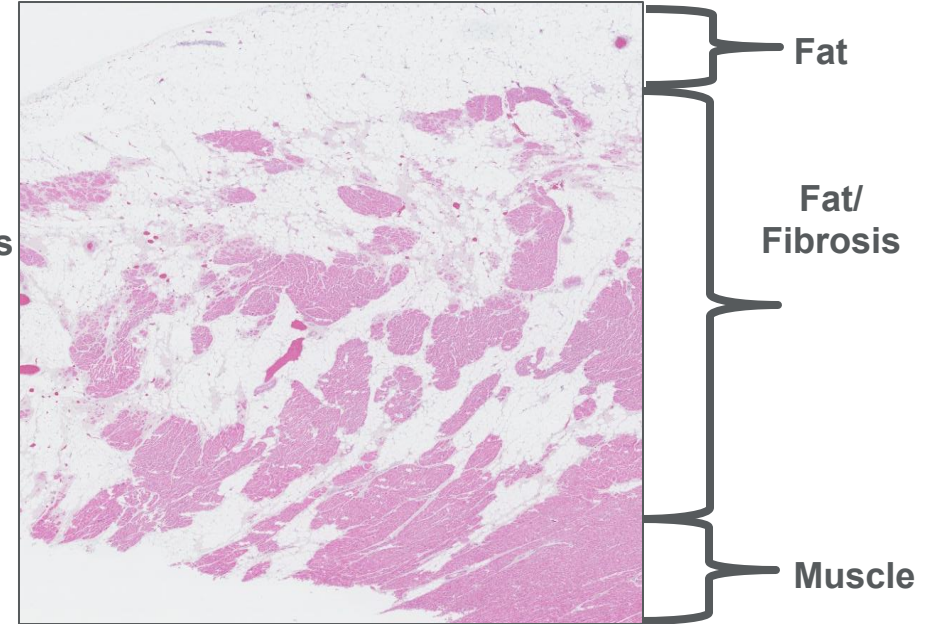


# Fibrofatty Replacement of Left Ventricle

Pre-teen

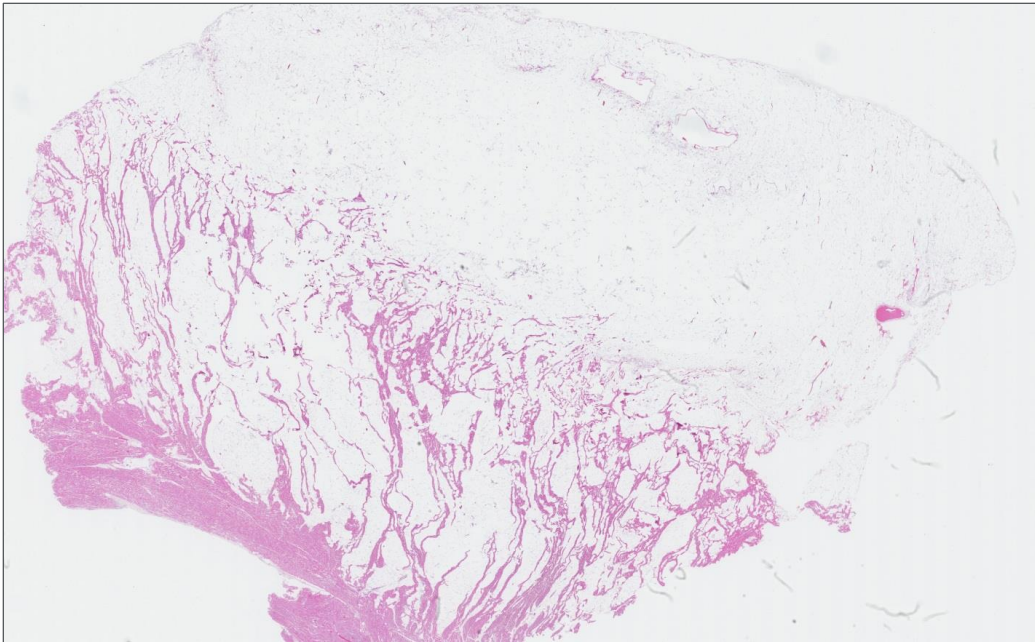


Adult

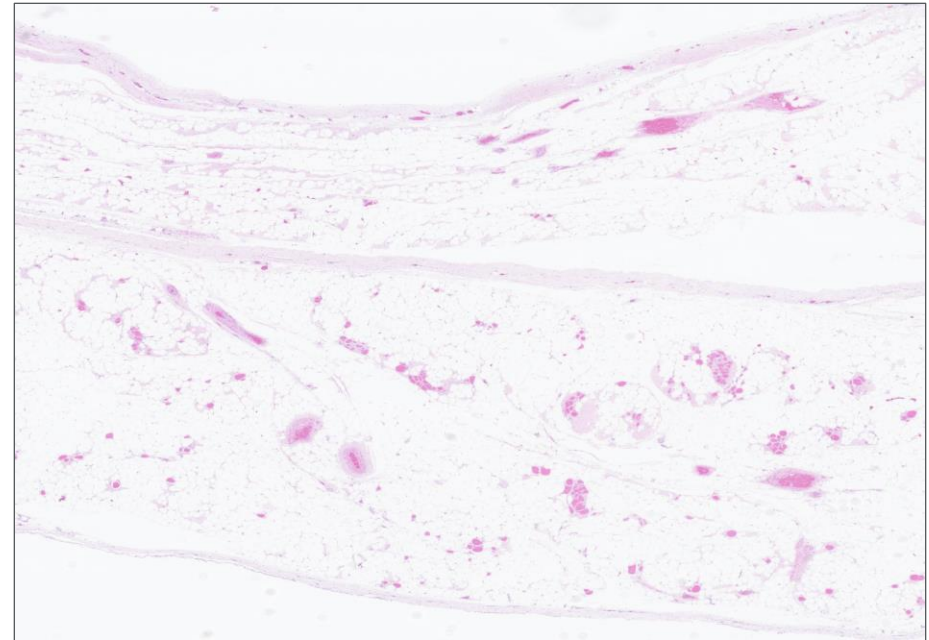


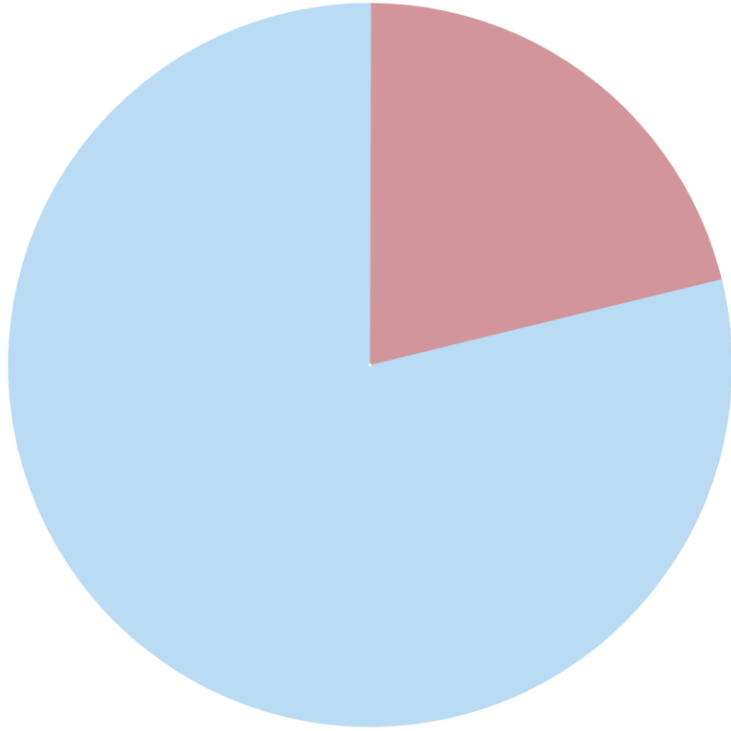
# Fibrofatty Replacement of Atrium and Right Ventricle

**Right Ventricle**

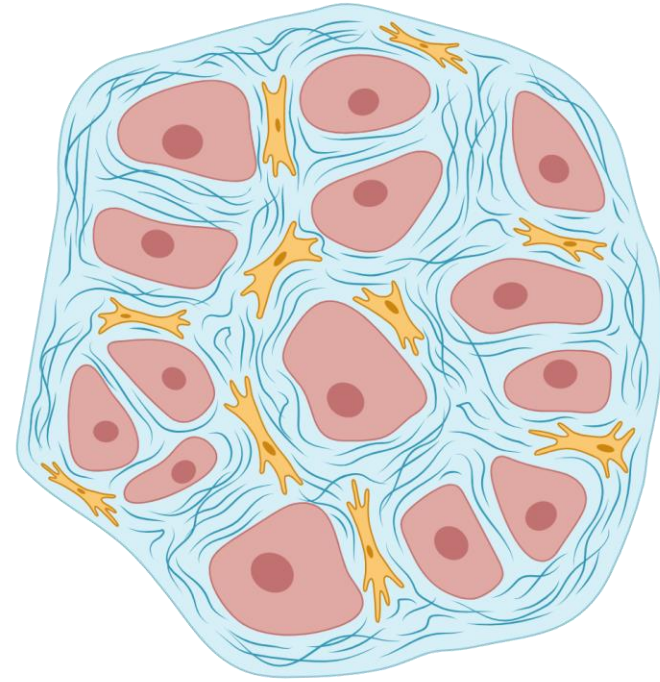


**Atrium**





20% Have Fibrosis  
Before Age 10



Microscopic  
Fibrosis

# Shifting Toward Early Treatment



Right  
Therapy

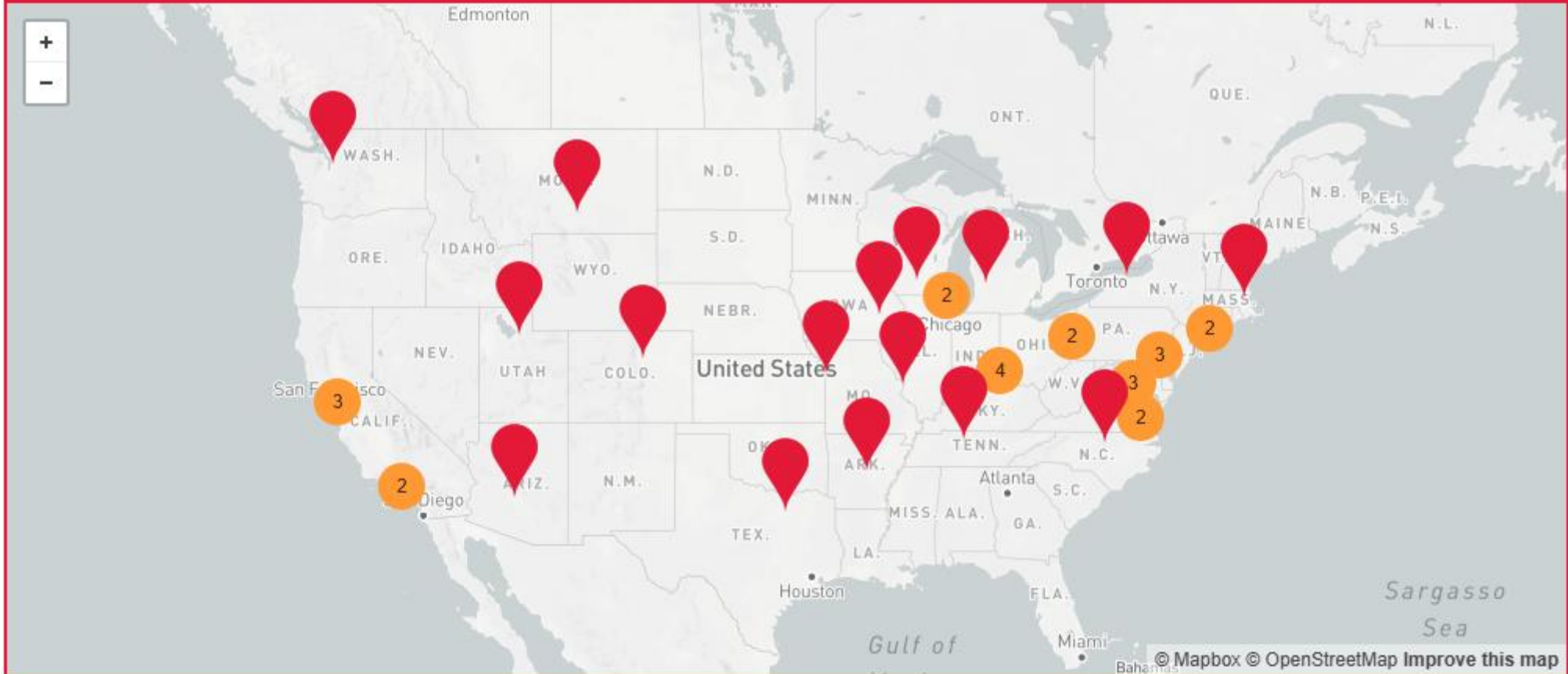

Right  
Time



Right  
Person

# Certified Duchenne Care Centers



Choose a Certified Care Center

# Thank you