3.1. Large mammal (canine) ECG (Spurney Lab)

Authors: Guo, LJ and Spurney, CF
Edited by Deb Fine

A. OBJECTIVE

Record electrocardiogram tracing in large mammals (dogs/ pigs) to analyze cardiac rhythm, conduction and structural abnormalities.

B. CAUTIONS

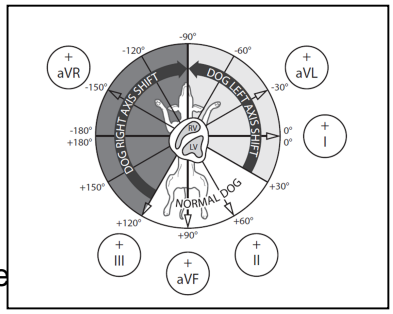

- The stress of animal during ECG recording
- Performing the exam on a non-conductive table surface
- Any artifacts from animal's motion or machine connection
- Respiratory status of GRMD dogs during the exam

C. MATERIALS

- ECG machine with leads – clinical machines are appropriate
  - Philips PageWriter Trim III ECG or similar
  - AliveCor Veterinary Heart Monitor
- ECG patches
- ECG gel
- Electric hair Clipper
- Cloth tape

D. METHODS

1. Shave hair on dorsal pedal surface of legs for ECG patches (ECG gel is applied).
2. Shave hair on the chest.
3. Gently restrain the animal in right lateral recumbency.
4. Regular ECG connections:

ECG patches for 6 leads: left forelimb, right forelimb, left hindlimb, right hindlimb

Lead I – right forelimb (-) to left forelimb (+)

Lead II – right forelimb (-) to left hindlimb (+)
Lead III – left forelimb (-) to left hindlimb (+)
Lead aVR – a point (-) halfway between left forelimb and left hindlimb to right forelimb (+)
Lead aVL – a point (-) halfway between right forelimb and left hindlimb to left forelimb (+)
Lead aVF – a point (-) halfway between right forelimb and left forelimb to left hindlimb (+)

5. Calculate the intercostal space from the 13th rib, and find 5th and 6th intercostal spaces.

6. Lead V1 patch is positioned at right 5th intercostal space near animal's sternum.
7. Lead V2 patch is positioned at left 6th intercostal space near animal's sternum.
8. Lead V4 patch is positioned at left 6th intercostal space near costochondral junction.
9. ECG is recorded at 25 or 50 mm/sec speed, 10 mm/mV amplitude.

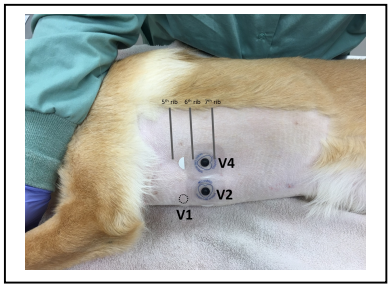

10. Use Philips ECG machine to record a 2 minutes Lead II continuous ECG for rhythm analysis.
11. Remove the chest ECG patches and disconnect the cables from the legs.

Alternative Method – use of AliveCor Vet phone application for rhythm analysis:

1. Place AliveCor ECG case (with gel) on animal's left side chest (following the long axis of heart). The top of ECG case towards to sternum (apical direction); the end of ECG case towards to heart base.
2. Record a two-minutes precordial ECG lead at the speed of 25 mm/sec for rhythm analysis.

E. EVALUATION AND INTERPRETATION OF RESULTS

- Heart rate
- Arrhythmias
- Ventricular axis
- Waveforms: Waveforms are measured at 50 mm/sec in lead II recording. These usually include P wave amplitude and duration, PR interval, QRS duration, R wave amplitude and Q-T duration. Additionally, Q/R ratio and R/S ratio can be calculated from V1, V2, V4 recording. For GRMD affected dogs, Q/R ratios in Lead II, III and aVF are also useful.

F. REFERENCES

1. Moise, N. S., Valentine, B. A., Brown, C. A., Erb, H. N., Beck, K. A., Cooper, B. J., & Gilmour, R. F. (1991). Duchenne's cardiomyopathy in a canine model: electrocardiographic and echocardiographic studies. J Am Coll Cardiol, 17(3), 812-820.
2. Fine, D. M., Shin, J. H., Yue, Y., Volkmann, D., Leach, S. B., Smith, B. F., . . . Duan, D. (2011). Age-matched comparison reveals early electrocardiography and echocardiography changes in dystrophin-deficient dogs. Neuromuscul Disord, 21(7), 453-461. doi: 10.1016/j.nmd.2011.03.010
3. Figure 1: Gordon SG, Estrada AH. The ABCDs of Small Animal Cardiology: A Practical Manual. 1st ed. Guelph, Canada: LifeLearn Inc.; 2013.